

**Anti-Ulcerogenic Effect of Unripe Plantain (*Musa paradisiaca*) Pulp on Indomethacin-Induced Ulcer in Wistar Rat**Augustine C. Madueke¹, Diane O. Ugwu¹, Valentine O. Nwanelo^{1*}, Assumpta C. Anosike¹, Rapheal C. Anajemba², Pearl A. Onoh¹¹Ethnopharmacology, Food and Drug Delivery Research Group, Department of Biochemistry, Faculty of Biological Sciences, University of Nigeria, Nsukka
²Department of Plant Science and Biotechnology, Faculty of Biological Sciences, University of Nigeria, Nsukka, Enugu State, Nigeria

ARTICLE INFO

ABSTRACT

Article history:

Received 12 August 2020

Revised 08 September 2020

Accepted 31 October 2020

Published online 02 November 2020

Copyright: © 2020 Madueke *et al.* This is an open-access article distributed under the terms of the [Creative Commons Attribution License](https://creativecommons.org/licenses/by/4.0/), which permits unrestricted use, distribution, and reproduction in any medium, provided the original author and source are credited.

Musa Paradisiaca has been used in traditional medicine for the treatment of ulcer and our study evaluated the potentials of *Musa paradisiaca* pulp for the management of ulcer using a standard experimental animal model. The phytochemical, acute toxicity and histological studies of *Musa paradisiaca* pulp were carried out according to standard methods. The possible anti-ulcer potential investigation was done using 25 rats of 5 rats per group. The animals were administered distilled water 3 mL/kg, extract (100, 200 and 400 mg/kg), cimetidine 100 mg/kg. Ulcer was induced by oral administration of indomethacin (200 mg/kg). No death was recorded in animals that received extract up to 5000 mg/kg body weight. Our data showed that *Musa paradisiaca* pulp contains flavonoids, tannins, saponins, glycosides, steroids, alkaloids, resins and reducing sugars. The extract showed a significant reduction ($p < 0.05$) in mean ulcer index (1.50 ± 0.38 , 1.63 ± 0.34 and 1.05 ± 0.29) in animals treated with the extract at all doses relative to untreated control (2.18 ± 0.29). A correlation coefficient of 0.728 existed between percentage inhibition and different concentrations of the extract. The Percentage Ulcer Inhibition of *Musa paradisiaca* pulp varied with doses. The Percentage Ulcer Inhibition of the extract at 400 mg/kg (51.83%) compared favorably with cimetidine (49.54%). The anti-ulcer studies showed considerable ulcer inhibition (31.19%, 25.23% and 51.83%) by *Musa paradisiaca* pulp which was confirmed by the results of histological studies. It is concluded that *Musa paradisiaca* pulp possesses anti-ulcerogenic effects which could be attributed to its phytochemical profile.

Keywords: *Musa paradisiaca*, Anti-Ulcerogenic, Indomethacin, Cimetidine, Gastric Ulcer.

Introduction

The proportion of the human population with ulcer has recorded a geometric up-shoot recently, especially in Nigeria.¹ Peptic ulcer disease (PUD) is a common and pronounced ailment across the globe. Global Burden of Disease estimated that PUD was responsible for over 300 000 deaths in 2013 globally.² PUD was identified as the leading cause of death among emergent surgical conditions with a rate of 3.5 per 100,000 deaths.³ The high morbidity and substantial mortality of PUD has made it the most predominant gastrointestinal disease posing adverse threats to the world's population.⁴ This could be attributed to the myriads of the predisposing factors ranging from *H. pylori* infection, non-steroidal anti-inflammatory drugs (NSAIDs), pepsin, smoking, alcohol, bile-acids, steroids, stress and changes in gastric mucin consistency.⁵ This increase in incidence has raised a public health concern.

Drug-induced ulceration caused by non-steroidal anti-inflammatory drugs (NSAIDs) is possibly achieved through impairment of the mucosal defensive mechanisms, suppression of prostaglandin synthesis, reduction of gastric mucosal blood flow and interference with the repair of superficial injury.⁶⁻⁷

*Corresponding author. E mail: valentine.nwanelo@unn.edu.ng
Tel: +2348036847294

Citation: Madueke AC, Ugwu DO, Nwanelo VO, Anosike AC, Anajemba RC, Onoh PA. Anti-Ulcerogenic Effect of Unripe Plantain (*Musa Paradisiaca*) Pulp on Indomethacin-Induced ulcer in Wistar Rat. Trop J Nat Prod Res. 2020; 4(10):784-789. doi.org/10.26538/tjnpr/v4i10.20

Official Journal of Natural Product Research Group, Faculty of Pharmacy, University of Benin, Benin City, Nigeria.

Medicinal plants have been helpful in the management of human diseases as reported by various research findings. The use of *Musa paradisiaca* (plantain) in the treatment of human diseases has been reported in various parts of the world.⁸ The pharmacological activities of the fruits, stem juice and flowers of *Musa paradisiaca* have been documented by various researchers.⁹⁻¹²

Although various studies have been conducted with different parts of the plant, the pharmacological properties of the unripe fruit pulp remains unexploited.¹³ Moreso, there is a claim about the traditional use of the unripe fruit pulp in the management of ulcer. The study evaluated the anti-ulcer properties of unripe plantain fruit pulp.

Materials and Methods*Plant collection and extraction*

Unripe mature pulps of *Musa paradisiaca* were obtained in June, 2015 from Ekeugwu market, Ukehe Town in Igbo-Etiti Local Government Area, Enugu State of Nigeria. Identification was done by a taxonomist in Bioresources Development and Conservation Programme (BDPC) research center, Nsukka, Enugu State, Nigeria and a voucher specimen (#Interceed/790), was deposited at the herbarium for references purposes. The fleshy unripe fruits of *Musa paradisiaca* were peeled, sun-dried and pulverized into powder with a mechanical grinder. A mass of 865.5 g of the powdered sample of the unripe *Musa paradisiaca* pulp was obtained. Cold distilled water was used for the extraction by soaking 865.5 g of *Musa paradisiaca* in 1 L of distilled water and placed on a mechanical shaker for forty-eight (48) hours. It was then filtered with filter paper and concentrated using rotary

evaporator. Afterwards, it was dried in an oven with hot air at 60°C. The concentrate was then evaluated for anti-ulcer activity.

Chemicals, reagents and equipment.

The chemicals, reagents and kits used in this research were of analytical grade except chloroform. Equipment were either bought or gotten from the Department of Biochemistry and Department of Veterinary Medicine, University of Nigeria, Nsukka, and Shalom Chemical Laboratories, Nsukka, Enugu state. The equipment included: Magnetic stirrer, weighing balance, metal cages, measuring cylinders and beakers, syringes.

Experimental animals

Eighteen (18) Swiss mice and Twenty-five (25) adult Wistar rats of both sexes, between 10 to 16 weeks old with an average weight of 30 ± 10 g and 150 ± 25 g, respectively, were used. The animals were acclimatized for Seven (7) days under standard environmental conditions, with a 12-hour light/dark cycle maintained on feed (vita feed) and water *ad libitum*. The ethical clearance for the experimental animals was obtained from the Ethical clearance Committee for Biological Sciences, University of Nigeria, Nsukka with approval number, UNN/FBS/EC/1033.

Phytochemical and macronutrients analyses of *Musa paradisiaca* pulp
The qualitative phytochemical and macronutrient analyses were done using previously described methods.¹⁴⁻¹⁵

Acute toxicity test of *Musa paradisiaca* pulp

Acute toxicity study was carried out using the method of Lorke.¹⁶ The study was carried out in two phases with eighteen (18) Swiss mice. For each phase, nine (9) mice divided into three groups of three (3) animals each were employed. For phase I, groups 1, 2 and 3 received 10, 100 and 1000 mg/kg of *Musa paradisiaca* pulp, respectively and observed for behavioral changes and/or death for 24 hours. For phase II, groups 1, 2 and 3 were administered 1600, 2900 and 5000 mg/kg body weight of *Musa paradisiaca* pulp, respectively and monitored for changes in behavior or death for 24 hours.

Experimental design

Twenty-five (25) adult Wistar rats used were randomly divided into five groups of five animals each. The animals were administered distilled water 3 mL/kg, extract (100, 200 and 400 mg/kg), cimetidine 100 mg/kg. Ulcer was induced by oral administration of indomethacin at a dose of 200 mg/kg b.w according to the method to the previously described method thirty minutes after pretreatment with either distilled water, extract or cimetidine.¹⁷ After eight (8) hours, animals were sacrificed and scored accordingly.

Determination of the mean ulcer index

Levels of ulceration in the animals were estimated according to the method of Szabo and Hollander.¹⁸ Briefly, stomachs were washed with normal saline, pinned against a white corkboard and ulcers were scored using dissecting microscope with square-grid eyepiece on a 0–5 scale according to the severity of the lesions. Areas of mucosal damage were expressed as a percentage of the total surface area of the glandular stomach in square millimeters. Mean ulcer score for each animal was determined and used to calculate the ulcer index and percentage ulcer inhibition as follows:

$$\text{Mean Ulcer Index} = 1 - \frac{\text{Ulcer}_{\text{treated}}}{\text{Ulcer}_{\text{control}}}$$

$$\text{Percentage Ulcer inhibition} = 1 - \frac{\text{Ulcer}_{\text{treated}}}{\text{Ulcer}_{\text{control}}} \times 100$$

Histological studies

Histological studies followed previously described method.¹⁹ Stomach tissues were fixed in paraffin and thin sections (5 µM) were cut, stained using hematoxylin and eosin (H & E) dye and examined microscopically.

Statistical analysis

One-way analysis of variance was used for data analysis. Correlation analysis was used to determine the relation between % ulcer inhibition and the doses of the fruit pulp studied. Values are mean ± standard deviation (S.D) and P values of P ≤ 0.05 were considered statistically significant.

Results and Discussion

Phytochemical analysis of *Musa paradisiaca* pulp, showed the presence of flavonoids, alkaloids, tannin, glycosides, reducing sugar, cardiac glycosides, carbohydrates, saponins, resins and steroids, corroborates previous reports.²⁰⁻²¹ (Table 1). The presence of polyphenols amongst other phytonutrients could account for the ulcer inhibitory properties of *Musa paradisiaca* fruit pulp. Polyphenols have been known to protect the mucosa through enhancing cellular proliferation, secretion of mucus, increasing mucus resistance, antioxidant effect, inhibiting HCl secretion and thus preventing ulceration.²² These bioactive components may have acted synergistically to achieve the anti-ulcerogenic activities of *Musa paradisiaca* pulp.²²⁻²⁶

The fruit pulp caused no death of animals up to a dose of 5000 mg/kg body weight and thus suggests that the fruit pulp is safe for oral administration (Table 2). *Musa paradisiaca* pulp is safe for consumption at all doses studied and corroborates previous report.¹³ The ulceration following oral administration of indomethacin in the rats may be attributed to either free radicals formation or inhibition of prostaglandin synthesis. Decreased prostaglandin level has been attributed to impaired gastro protection and increased gastric acid secretion, which are important events in the etiology of mucosal ulceration.²⁵ Table 3 shows the mean ulcer index and percentage ulcer inhibition of the experimental groups. The negative control recorded the highest mean ulcer index (2.18 ± 0.66) relative to the treated groups (1.50 ± 0.38, 1.63 ± 0.34, 1.05 ± 0.29 and 1.10 ± 0.27). The fruit pulp at a dose of 400 mg/kg produced a significantly lower ulcer index (1.05 ± 0.29) relative to the standard drug (1.10 ± 0.27). The percentage ulcer inhibition showed that significant ulcer inhibition between the negative control and the treated groups (31.19%, 25.23%, 51.83% and 49.54%). Percentage ulcer inhibition revealed that the fruit pulp at a dose of 400 mg/kg (51.83%) inhibited indomethacin-induced ulcer more than cimetidine (49.54%). However, the reduction observed in pre-treated animals indicated that there was reduction in ulceration in treated rats compared to the negative control. The percentage inhibition showed the degree of the anti-ulcer activity of *Musa paradisiaca* pulp, which was dose-dependent with a positive correlation coefficient. These results are in contrast to earlier reports which indicated no activity on indomethacin-induced ulcer.¹³ This might be as a result of increase in abundance of anti-ulcer ingredients with respect to the varied doses.

Table 1: Phytochemical Constituents of dried powdered of *Musa paradisiaca* pulp.

Phytochemicals	Inference
Alkaloids	+
Glycosides	+
Reducing sugar	+
Cardiac glycosides	+
Carbohydrates	+
Flavonoid	+
Tannins	+
Saponins	+
Resins	+
Steroids	+

Key: + indicates present.

Figure 1 shows a strong positive correlation between graded doses (100, 200 and 400 mg/ kg body weight) of dried powdered *Musa paradisiaca* pulp and percentage ulcer inhibition.

The disruption of inner surface of the stomach morphology and severity of haemorrhage and ulceration, caused by indomethacin induction are shown in Plates 1 to 5.

The anti-ulcer effect of *Musa paradisiaca* pulp was confirmed by histopathological analysis on the stomach tissue of control and treated animals (Plates 6 to 10). In Plate 10, the cimetidine treated group showed less severe disruption of the epithelium and necrotic lesion, penetrating deeply into the mucosa, which is associated with haemorrhage surrounded by dense glands, leukocyte infiltrations and ulcer region with vascular granulation tissue and fibroblasts. Groups treated with *Musa paradisiaca* pulp, however, showed relative reduction of the effect of the ulcer compared to the control group (Plate 1). Progressive reduction in ulceration of the stomach tissues was observed with respect to varied doses.

Table 2: Acute toxicity test result of *Musa paradisiaca* pulp on Swiss mice.

Phase I	Dosage (mg/kgbw)	Mortality
Group 1	10	0/3
Group 2	100	0/3
Group 3	1000	0/3
Phase II		
Group 1	1600	0/3
Group 2	2900	0/3
Group 3	5000	0/3

n = 3

Table 3: Percentage ulcer inhibition of dried powdered *Musa paradisiaca* pulp on Wistar rats.

Groups	Mean ulcer index	% ulcer inhibition
1	2.18 ± 0.66 ^c	-
2	1.50 ± 0.38 ^b	31.19
3	1.63 ± 0.34 ^{a,b,c}	25.23
4	1.05 ± 0.29 ^a	51.83
5	1.10 ± 0.27 ^{a,b}	49.54

Values are presented as mean ± standard deviation, n=5

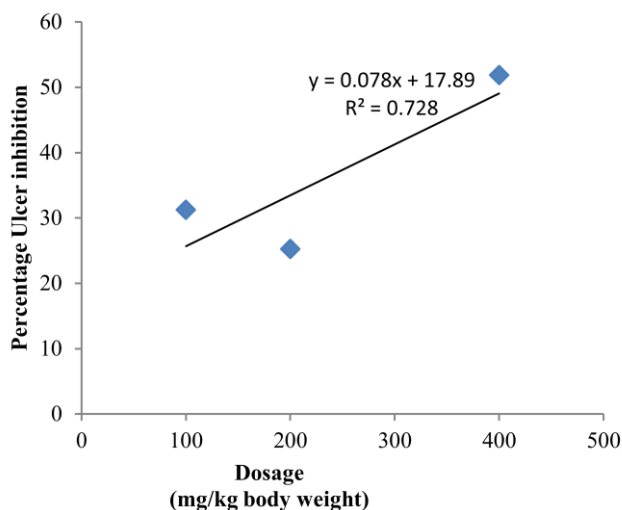


Figure 1: Scatter plot of Percentage ulcer Inhibition against doses of dried powdered *Musa paradisiaca* fruit Pulp.

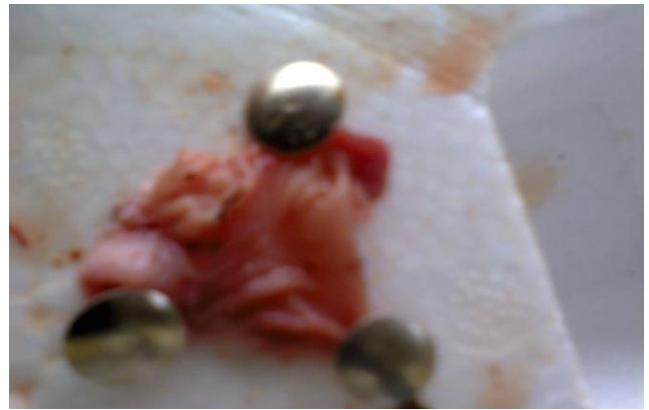

Plate 1: Group 1 = Negative control

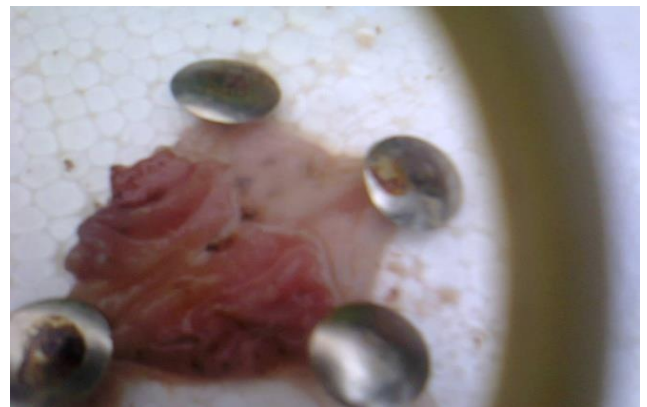

Plate 2: Group 2 = 100 mg/ kg extract

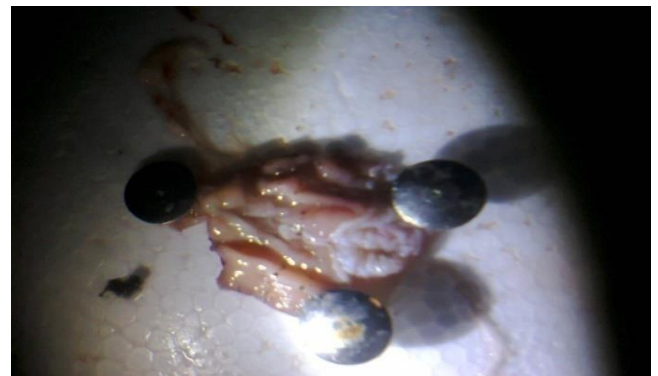


Plate 3: Group 3 = 200 mg/ kg extract

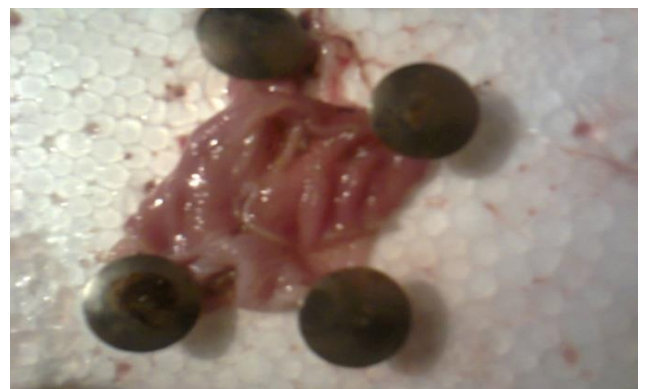

Plate 4: Group 4 = 400 mg/ kg extract

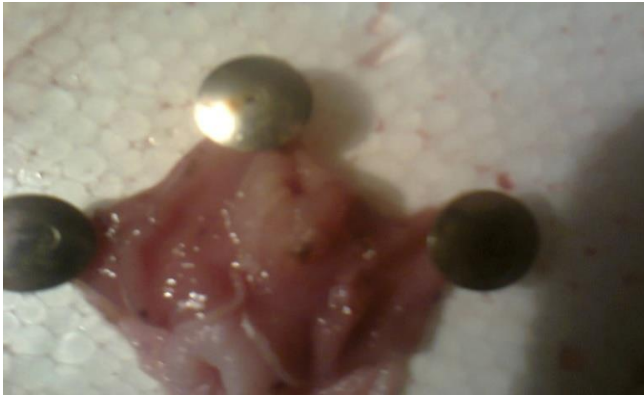

Plate 5: Group 5 = 100 mg/kg cimetidine

Conclusion

Generally, the study showed that *Musa paradisiaca* has significant ulcer healing effect on indomethacin-induced gastric ulcer. Traditionally, *Musa paradisiaca* has been used in the treatment of gastric ulcer and other ailments. The present study supports this local claim and suggests that the ulcer healing properties of *Musa paradisiaca* pulp may be attributed to the presence of flavonoids/polyphenolic compounds.

Conflict of Interest

The authors declare no conflict of interest.

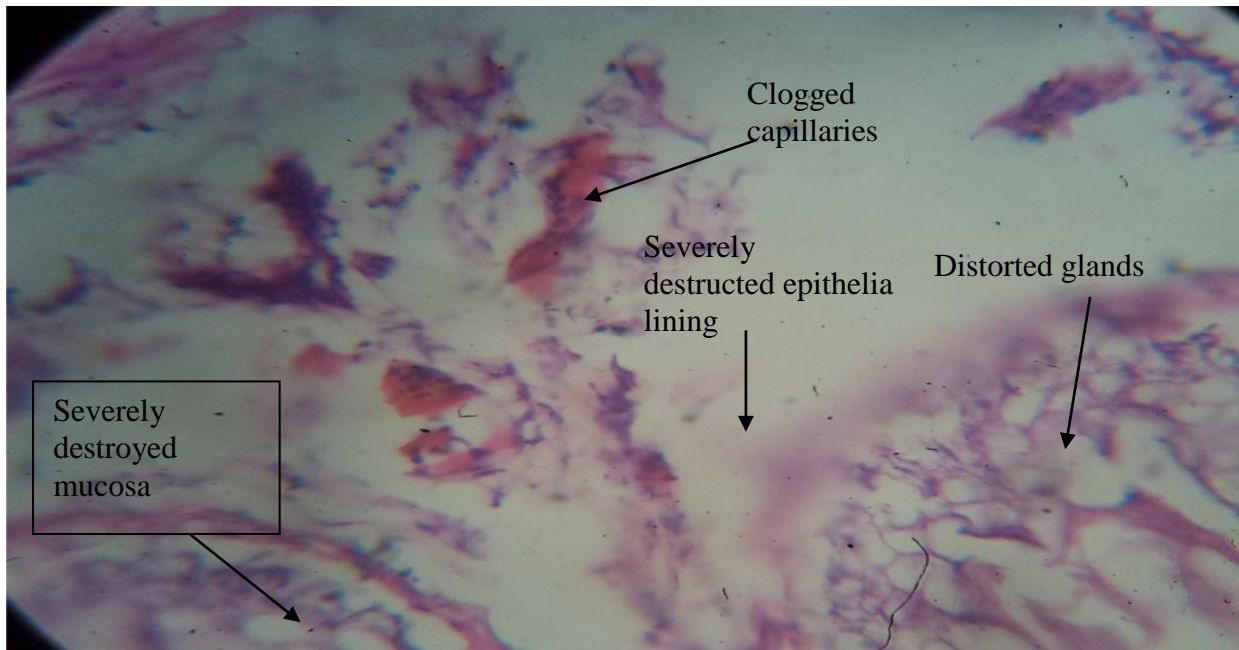


Plate 6 (Group 1): Regions of distorted glands, clogged capillaries, severely destroyed mucosa and epithelia lining. H&E Mag x400.

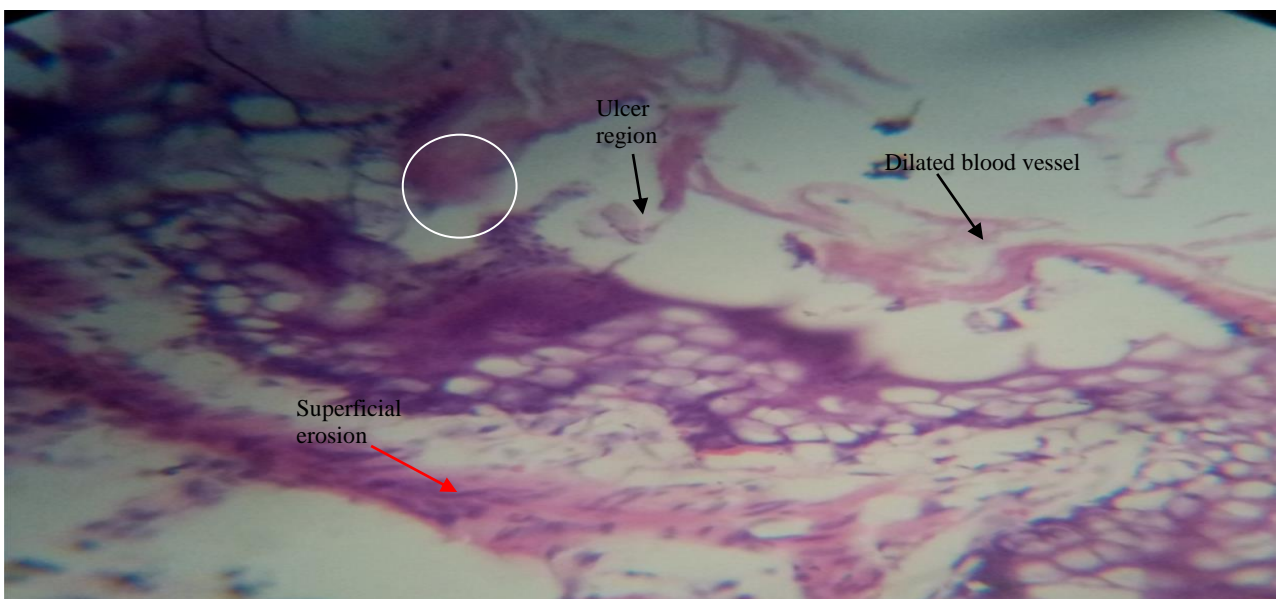


Plate 7 (Group 2): Regions showing ulcer region, dilated blood vessels and small superficial erosion. H&E Mag x400.

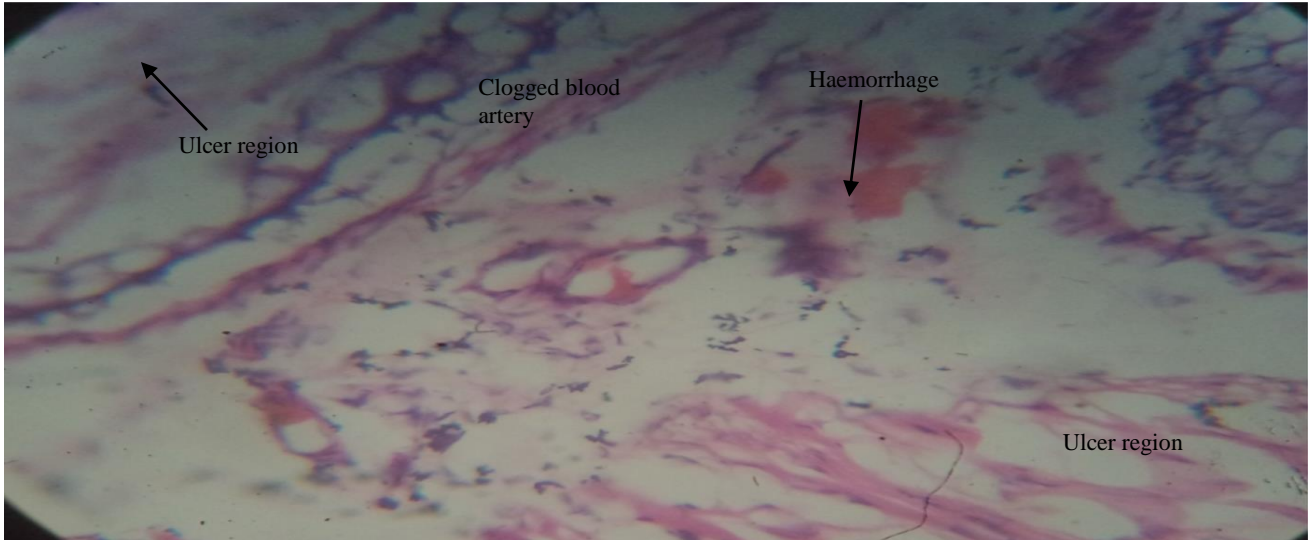


Plate 8 (Group 3): Regions showing haemorrhage, clogged blood artery and ulcer region. H&E Mag x400.

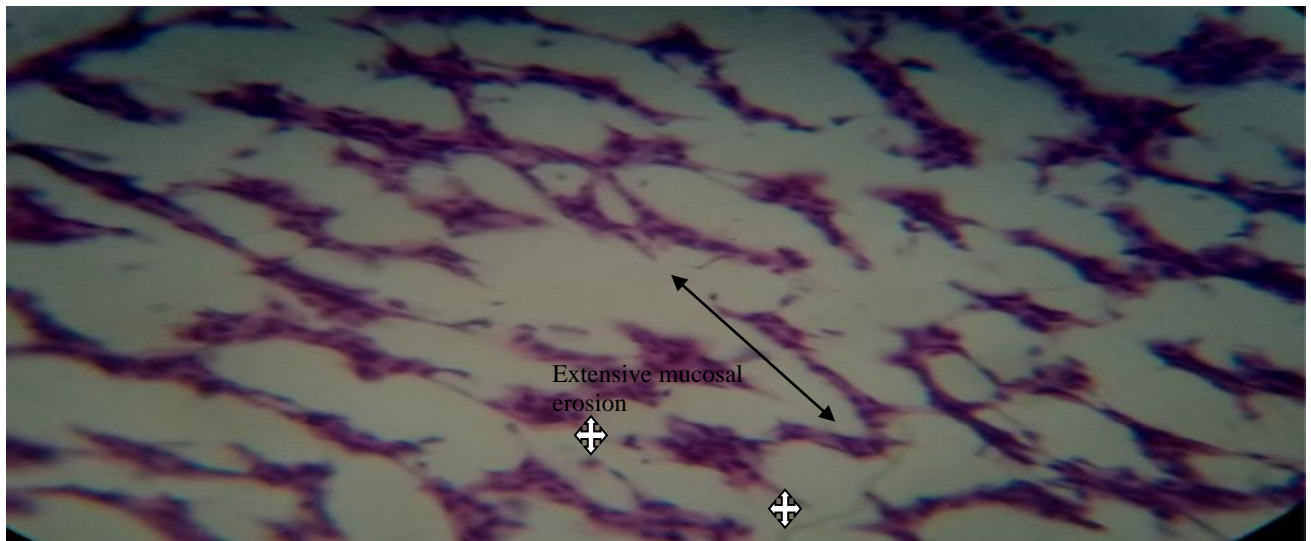


Plate 9 (Group 4): Infiltration of leukocytes (whites cross). External mucosal erosion (black arrow) which is also keeping for chronic ulcer. H&E. Magx400.

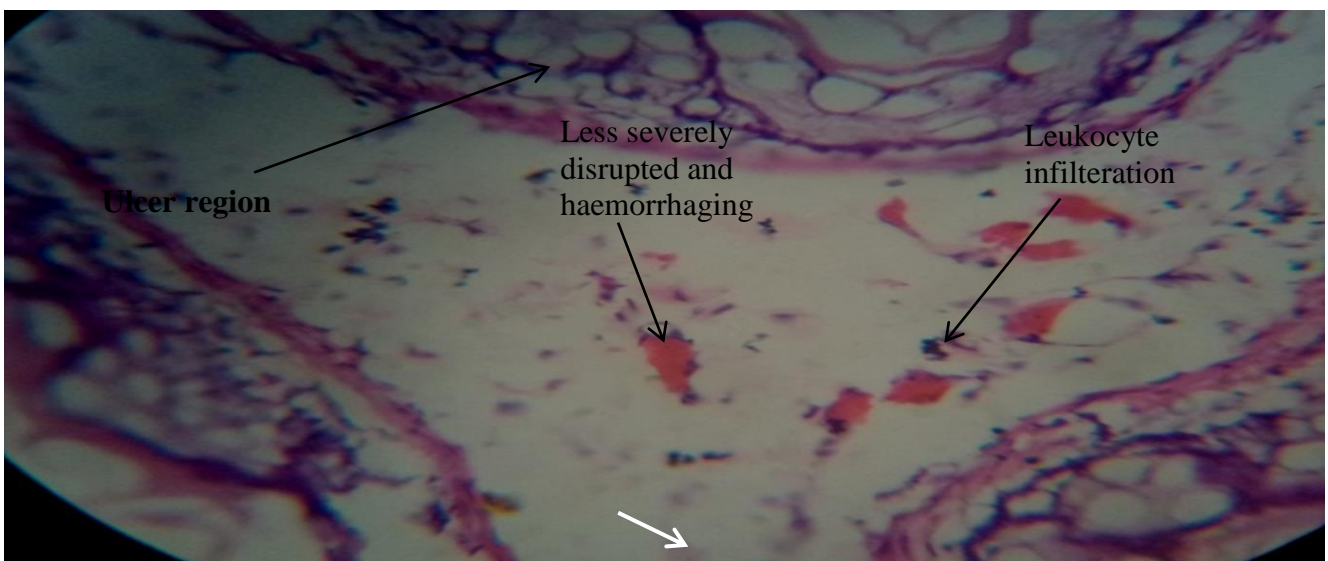


Plate 10 (Group 5): Regions showing less severely disrupted and haemorrhaging epithelium, leukocyte infiltration and ulcer site. H&E Mag x400.

Authors' Declaration

The authors hereby declare that the works presented in this article are original and that any liability for claims relating to the content of this article will be borne by them.

References

- Dongo AE, Uhumwagho O, Kesieme EB, Eluehike SU, Alufuhai EF. "A Five-Year Review of perforated peptic ulcer disease in Irrua, Nigeria". Int Sch Res Notices. 2017. Article ID 8375398.
- Abubakar I and Tillmann T. Mortality and Causes of Death Collaborators. Global, regional, and national age-sex specific all-cause and cause-specific mortality for 240 causes of death, 1990- 2013: a systematic analysis for the global burden of disease study 2013. Lancet 2015; 385:117-171
- Wang J, Fang X, Ge L, Cao F, Zhao L, Wang Z. Antitumor, antioxidant and anti-inflammatory activities of kaempferol and its corresponding glycosides and the enzymatic preparation of kaempferol. PLoS ONE 2018; 13(5):1-12.
- Peter M, Chan FL, Kenneth EL. Peptic ulcer disease. Lancet 2009; 374:1449-1461
- Mustafa M, Menon J, Muiandy RK, Fredie R, Sein MM, Fariz A. Risk Factors, Diagnosis and Management of Peptic Ulcer disease. IOSR-JDMS. 2015; 14(7):40-46
- Ivey KJ. Mechanisms of Nonsteroidal Anti-Inflammatory Drug-Induced Gastric Damage. Am J Med. 1988; 84(2):41-48.
- Wallace JL. How do NSAIDs cause ulcer disease? Ballieres Clin Gastroenterol. 2000; 14(1):147-159.
- Palombo EA. Phytochemicals from traditional medicinal plants used in the treatment of diarrhoea: modes of actions and effects on intestinal function. Phytoter Res. 2005; 20:717-724.
- Ojewole JA and Adewunmi CO. Hypoglycemic effect of methanolic extract of *Musa paradisiaca* (*Musaceae*) green fruits in normal and diabetic mice. Methods Find Exp Clin Pharmacol. 2003; 25(6):453.
- Mallick C, Maiti R, Ghosh D. Comparative study on Antihyperglycemic and Antihyperlipidemic effects of separate and composite extract of seed of *Eugenia jambolana* and root of *Musa paradisiaca* in Streptozotocin-induced diabetic male albino rat. IJPT. 2016; 5(1):27-33.
- Mallick C, Chatterjee K, Biswas M, Ghosh D. Antihyperglycemic effects of separate and composite extract of root of *Musa paradisiaca* and leaf of *Coccinia indica* in Streptozotocin-induced diabetic male albino rat. Afr J Trad Compl Altern Med. 2007; 4(3):362-371.
- Singh SK, Kesari AN, Rai PK, Watal G. Assessment of Glycemic Potential of *Musa paradisiaca* Stem Juice. IJCB. 2007; 22(2):48-52.
- Ezekwesili CN, Ghasi S, Adindu CS, Mefoh NC. Evaluation of anti-ulcer property of aqueous extract of unripe musa paradisiaca linn. Peel in wistar rats. Afr J Pharm Pharmacol. 2014; 8(39):1006-1011.
- Harborne JB. Phytochemical Methods (1st Ed): A guide to modern technique of plant. London: Chapman and Hall; 1973. 107-150 p.
- Trease GE and Evans WC. Pharmacognosy (13th Ed). London: Bailliere Tindall Books Publishers, Ltd; 1989. 1-105 p.
- Lorke D. Determination of acute toxicity. Arch. Toxicol. 1983; 53:275-279.
- Sayanti B, Susri C, Sandip KB. Healing Properties of Some Indian Medicinal Plants against Indomethacin-Induced Gastric Ulceration in Rats. J.Clin Biochem Nutr. 2007; 41(2):106-141.
- Szabo S and Hollander D. Pathways of Gastrointestinal Protection and Repair: Mechanisms of Action of Sucralfate. Am J Med. 1985; 86(6A):23-31.
- Drury RA, Wallington A, Cameroun SR. Carleton's Histological Techniques. New York: Oxford University Press; 1967. 4:279-280 p.
- Eleazu CO, Okafor PN, Ikpeama A. Total antioxidant capacity, nutritional composition and inhibitory activity of unripe plantain (*Musa paradisiaca*) on oxidative stress in alloxan induced diabetic rabbits. PJJN 2010; 9(11):1052-1057.
- Mahmood A, Ngah N, Omar MN. Phytochemical constituent and antioxidant activities in *Musa paradisiaca* flower. Eur J Sci Res. 2011; 66(2):311-318.
- Ezike AC, Akah PA, Nnamani EM, Okoli CO, Ojike FU, Eze FS, Chime CE, Azosiri JJ. "Studies on the Antiulcer and Gastrointestinal Effects of Stem Bark Extract of *Bridelia ferruginea*," JCIIM. 2011; 3(1):1-16.
- Calderon-Montano JM, Burgos-Moron E, Perez-Guerrero C, Lopez-Lazaro MA. A review on the dietary flavonoid kaempferol. Mini Rev Med Chem. 2011; 11(4):298-344.
- Sumbul S, Ahmad MA, Asif M, Akhtar M. Role of Phenolic compounds in Peptic ulcer: an overview. J Pharm Bioall Sci. 2011; 3(3):361-367.
- Demarque DP, Callejon DR, De Oliveira GG. The role of tannins as antiulcer agents: a fluorescence-imaging based study. Rev Bras Farmacogn. 2018; 28:425-432.
- Sabihi S, Garuba T, Sunmonu T, Ajani E, Sulyman A, Nurain I, Balogun A. Indomethacin-induced gastric ulceration in rats: Protective roles of *Spondias mombin* and *Ficus exasperata*. Toxicol Rep. 2015; 2:261-274.
- Lawal F, Garba K, Shuai'bu AB, Chedi BAZ. Evaluation of the Antiulcer Activity of Aqueous Seed Extract of *Moringa Oleifera* Lamarck (*Moringaceae*). Trop J Nat Prod Res. 2018; 2(3):140-144.
- Njoku UO, Uzowuru B, Oguogor MO. Gastro-protective Properties of *Acalypha torta* Leaf against HCl/Ethanol-Induced Ulceration. Trop J Nat Prod Res. 2020; 4(7):299-303.